
Siepsler slipknot for McCannel iris-suture fixation of subluxated intraocular lenses

David F. Chang, MD

In 8 cases that presented with symptomatic posterior chamber IOL subluxation, a McCannel polypropylene (Prolene®) suture was used with the Siepsler slipknot technique to successfully refixate the IOLs to the iris. There were no intraoperative complications, and a round pupil was preserved in all cases.

J Cataract Refract Surg 2004; 30:1170–1176 © 2004 ASCRS and ESCRS

In the absence of adequate capsular support, malpositioned posterior chamber intraocular lenses (IOLs) may require suture fixation to avoid recurrent subluxation. Options include scleral or iris suturing of 1 or both haptics.^{1–3} McCannel⁴ and Stark and coauthors⁵ describe a modified McCannel technique for suturing a posterior chamber IOL haptic to the iris. They describe making a separate corneal incision in the appropriate quadrant through which to tie the knot. However, in addition to requiring an extra incision, this technique requires lifting the haptic and midperipheral iris up toward the incision.

Siepsler described a slipknot technique for repairing iris defects through limbal incisions. This technique was used to successfully fixate 1 or both haptics in a consecutive series of 8 subluxated posterior chamber IOLs using only paracentesis incisions. In this article, the details of this procedure are described and the clinical results in these 8 patients presented.

Surgical Technique

All cases were videotaped. In each case, the subluxated posterior chamber IOL was first repositioned and recentered using Lester or Sinsky hooks through para-

centesis incisions after first injecting viscoelastic material into the anterior and posterior chambers. In 2 cases, a partially fixated and tipped IOL was elevated from the anterior vitreous using the Viscoat® (sodium chondroitin sulfate 4.0%–sodium hyaluronate 3.0%) posterior-assisted levitation (PAL) technique through a pars plana sclerotomy.⁶ In these and 1 additional case, an anterior vitrectomy was performed through either a pars plana sclerotomy or limbal incision. An assessment of residual capsular support was made after the iris was retracted or the pupil was expanded with iris hooks.

In 1 case both haptics were sutured to the iris. In the remaining 7 cases, only a single haptic was sutured. Where possible, the IOL was oriented along an axis that utilized any remaining capsular support. The unsupported haptic(s) was sutured using the following technique. After the pupil was slightly constricted with acetylcholine (Miochol®) (Figure 1, *A*), the optic was prolapsed forward until it was “captured” by the pupil (Figure 1, *B*). A 10-0 polypropylene (Prolene®) suture with a CIF-4 curved needle (Ethicon) was used for the McCannel suture. Two clear corneal paracentesis stab incisions were preplaced along the anticipated path of the CIF-4 needle’s entry and exit. The edge of the IOL optic was tilted upward with a Lester hook to better visualize the haptic as the needle was passed through the midiris stroma (Figure 1, *C* and *D*). Tenting up the iris with the haptic from behind reduced the tendency to take too large a bite of iris tissue because the needle entered on 1 side of the haptic and exited on the other. The CIF-4 needle was threaded into the lumen of the viscoelastic cannula that had been introduced through

Accepted for publication October 23, 2003.

From a private practice, Los Altos, California, USA.

The author has no financial interest in any material or method mentioned.

Reprint requests to David F. Chang, MD, 762 Altos Oaks Drive, Suite 1, Los Altos, California 94024, USA. E-mail: dceye@earthlink.net.

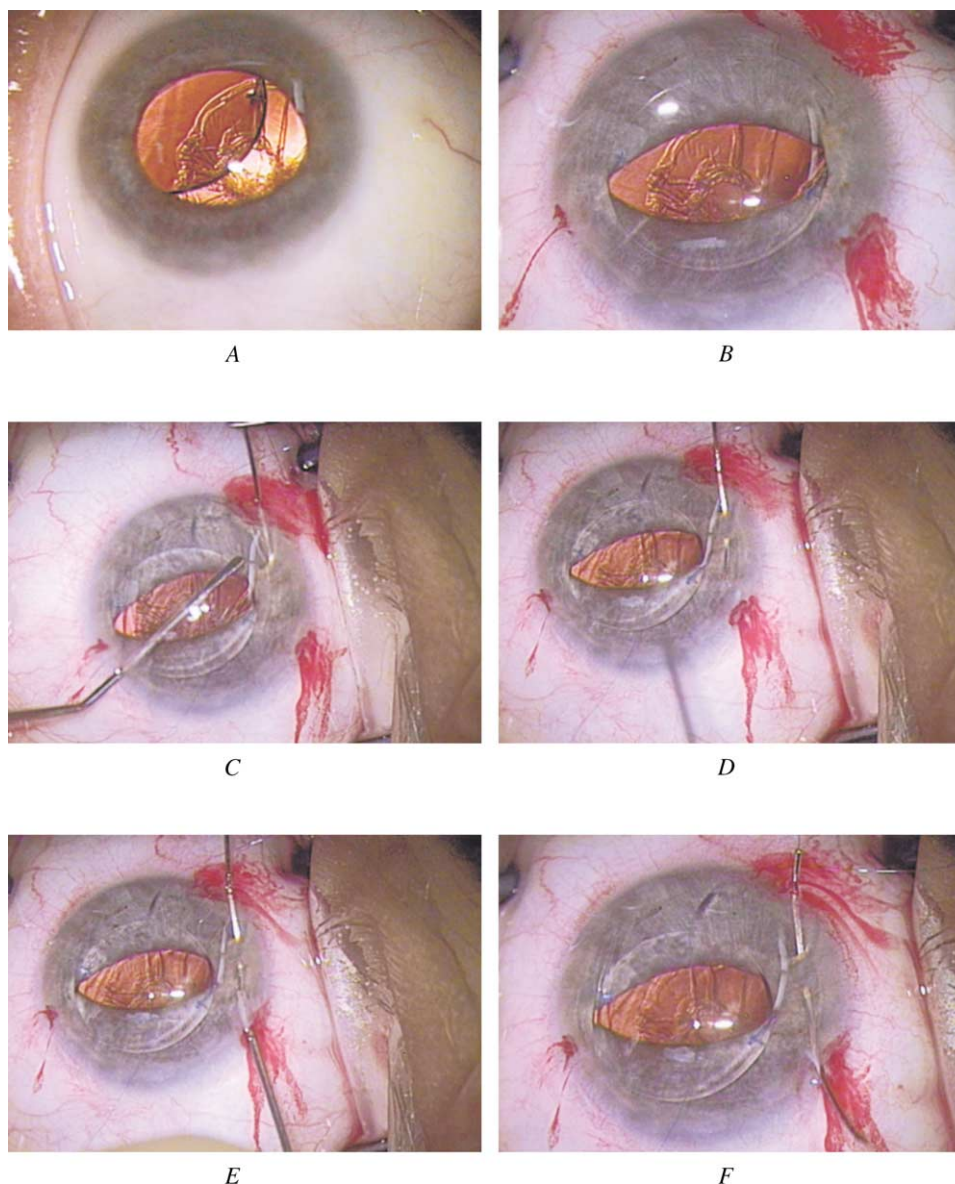


Figure 1. (Chang) Placement of modified McCannel iris suture. *A*: The pupil is constricted with Miochol. *B*: The IOL optic is prolapsed forward and captured by pupil. *C*: Lester hook tips the optic up, tenting the haptic against the iris stroma as the CIF-4 needle is passed. *D*: Needle weaves behind iris stroma, capturing the haptic. *E* and *F*: Needle tip is threaded into the lumen of viscoelastic cannula that guides the needle through the preplaced exit paracentesis. *B*–*F*: A white linear light reflex appears to the right of the optic. This artifact should not be confused with an instrument or needle.

the second paracentesis port to guide the needle out (Figure 1, *E* and *F*). Once the needle was cut off, the 10-0 Prolene suture extended from limbus to limbus, ensnaring the haptic as it weaved through the midperipheral iris stroma.

To tie the slipknot, an iris hook was used to retract a loop of suture distal to the haptic out through the proximal paracentesis port (Figure 2, *A* and *B*). The free proximal suture tip was passed through the loop in 2 throws (Figure 2, *C*). As each free end of the suture

was pulled, the knot slid down onto the haptic (Figure 2, *D*). The maneuver was repeated to lay down a second knot on top of the first. A long Vannas scissors was introduced through a slightly enlarged paracentesis opening to trim the suture ends (Figure 2, *E*). The optic was then repositioned back into the posterior chamber (Figure 2, *F*). The viscoelastic was removed using bimanual irrigation/aspiration handpieces.

Postoperative follow-up was individualized, depending on the patient's course. All patients were treated with

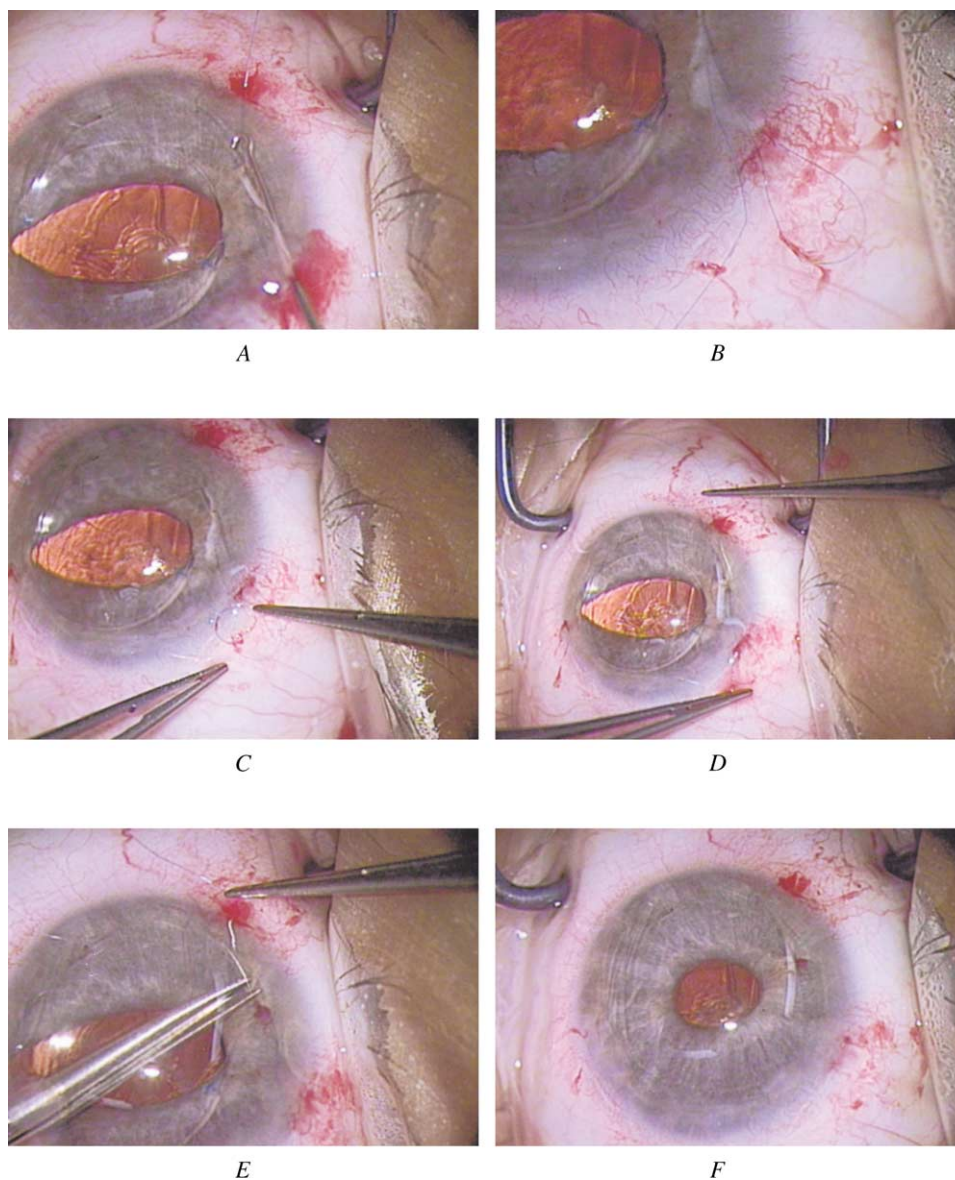


Figure 2. (Chang) Siepser slipknot technique for tying the modified McCannel iris suture. *A* and *B*: Iris hook passes distal to the haptic to draw a Prolene loop back out through the proximal paracentesis. *C*: After cutting off the needle, the free proximal suture end is passed twice through the loop. *D*: Opposite suture ends are pulled to lay slipknot down without displacing the haptic or iris. *E*: Long Vannas scissors are used through a third paracentesis incision to cut the suture tips. *F*: The IOL optic is repositioned back into the posterior chamber.

topical steroid and topical nonsteroidal anti-inflammatory medication.

Results

This series consisted of 8 consecutive eyes from 8 patients in whom this technique was performed by me to fixate subluxated posterior chamber IOLs. In each instance, the patient elected IOL repositioning surgery because of symptoms of edge glare or blurred vision. All patients had tried or been offered a trial of pilocarpine in

the affected eye. The patient data and surgical results are shown in Table 1. The mean age was 56 years. The interval from the original cataract surgery to the repositioning surgery ranged from 2 months to 5 years. In 1 case, the posterior capsule was intact, but the IOL lay within the sulcus. In 2 cases, the central capsule was intact, but there was a large zonular dialysis through which 1 haptic had rotated. In the remaining 5 cases, the posterior capsule had ruptured during the initial surgery.

An anterior vitrectomy was performed in 3 cases. Two of these also required elevation of part of the

Table 1. Patient characteristics and outcomes.

Patient	Age (y)	Surg Date	Time From Orig Surg	Preop BCVA	Postop BCVA	Number of Haptics Sutured	Vitrectomy	Follow-up	Defect in PC
1	68	7-01	4.5 y	20/50	20/25	1	Y +PAL	2 y	Y
2	51	7-01	2 y	20/20	20/25+	1	Y+PAL	2 y	Y
3	62	2-02	1 y	20/20	20/20	1	N	1 y	Y
4	37	4-02	5 y	CF	CF	1	N	1 y	Y
5	56	11-02	1 y	20/30	20/25	1	N	6 mo	Y
6	53	12-02	1 y	20/25	20/25	1	N	6 mo	N
7	66	12-02	3 mo	20/30	20/20	1	Y	6 mo	Y
8	53	5-03	2 mo	20/200	20/50	2	N	3 mo	Y

BCVA = best corrected visual acuity; CF = counting fingers; PAL = posterior assisted levitation with Viscoat; PC = posterior capsule

optic from the anterior vitreous using the Viscoat PAL technique through a pars plana sclerotomy.⁶ Intraoperatively, there were no instances of bleeding, iridodialysis, or posterior dislocation of the IOL.

The final best corrected visual acuity was 20/25 or better in 6 of 8 cases. It was 20/50 in 1 patient because of amblyopia caused by a traumatic cataract. Another patient was counting fingers pre- and postoperatively because of retinopathy of prematurity and nystagmus. This patient subsequently experienced mild posterior tilting of the nonfixated haptic but was not symptomatic. In all 8 eyes, the pupil was round and reactive postoperatively. There were no significant postoperative complications. Specifically, there were no instances of retinal detachment, cystoid macular edema, chronic iridocyclitis, or recurrent IOL subluxation. One patient was a steroid responder whose intraocular pressure was controlled with medication until the topical prednisolone could be tapered. The mean follow-up was 12 months, with a range of 3 months to 2 years.

Discussion

Surgical repositioning or exchange of a malpositioned posterior chamber IOL is an option to consider if significant edge glare is present. If feasible, repositioning the IOL avoids the larger incision and additional surgical manipulation required for an IOL exchange. This assumes that the original IOL is not damaged and is of the appropriate power. However, recurrent IOL subluxation may ensue if secure fixation is not attained. This could be because either the IOL is too short relative to the ciliary sulcus diameter or there is insufficient

capsular support. To prevent recurrent subluxation, the posterior chamber IOL can be sutured to the iris or sclera.¹⁻³ Depending on the amount and location of residual capsular support, 1 or both haptics can be suture fixated. If the capsular support is adequate but the IOL is too short, suture fixation of a single haptic is usually sufficient.

The American Academy of Ophthalmology Technology Assessment Committee recently reviewed the literature on IOL implantation in the absence of capsular support.³ They concluded that the literature supports the safety and efficacy of open-loop anterior chamber IOLs, scleral-sutured posterior chamber IOLs, and iris-sutured posterior chamber IOLs. In the absence of randomized comparative trials, there was insufficient evidence to determine which method of fixation is superior.

Scleral suture fixation can be performed by externalizing 1 haptic through an incision to tie a Prolene suture around it.⁷⁻¹⁰ Transscleral suture fixation can be associated with several problems, including IOL tilt, bleeding, rhegmatogenous retinal detachment, and external irritation from the Prolene knot.¹¹⁻¹⁴ Both ultrasound biomicroscopy and pathology specimens have demonstrated that precise anatomic fixation of the haptic to the ciliary sulcus is difficult to attain.^{15, 16} Finally, late IOL dislocation because of suture failure has been described.¹⁷⁻¹⁹ Although 9-0 Prolene should theoretically last longer than 10-0 Prolene, long-term studies will be needed to confirm this.

With respect to reports of sutured IOLs in the literature, iris-fixated posterior chamber IOLs are in the minority.³ Until recently, most of these reports described

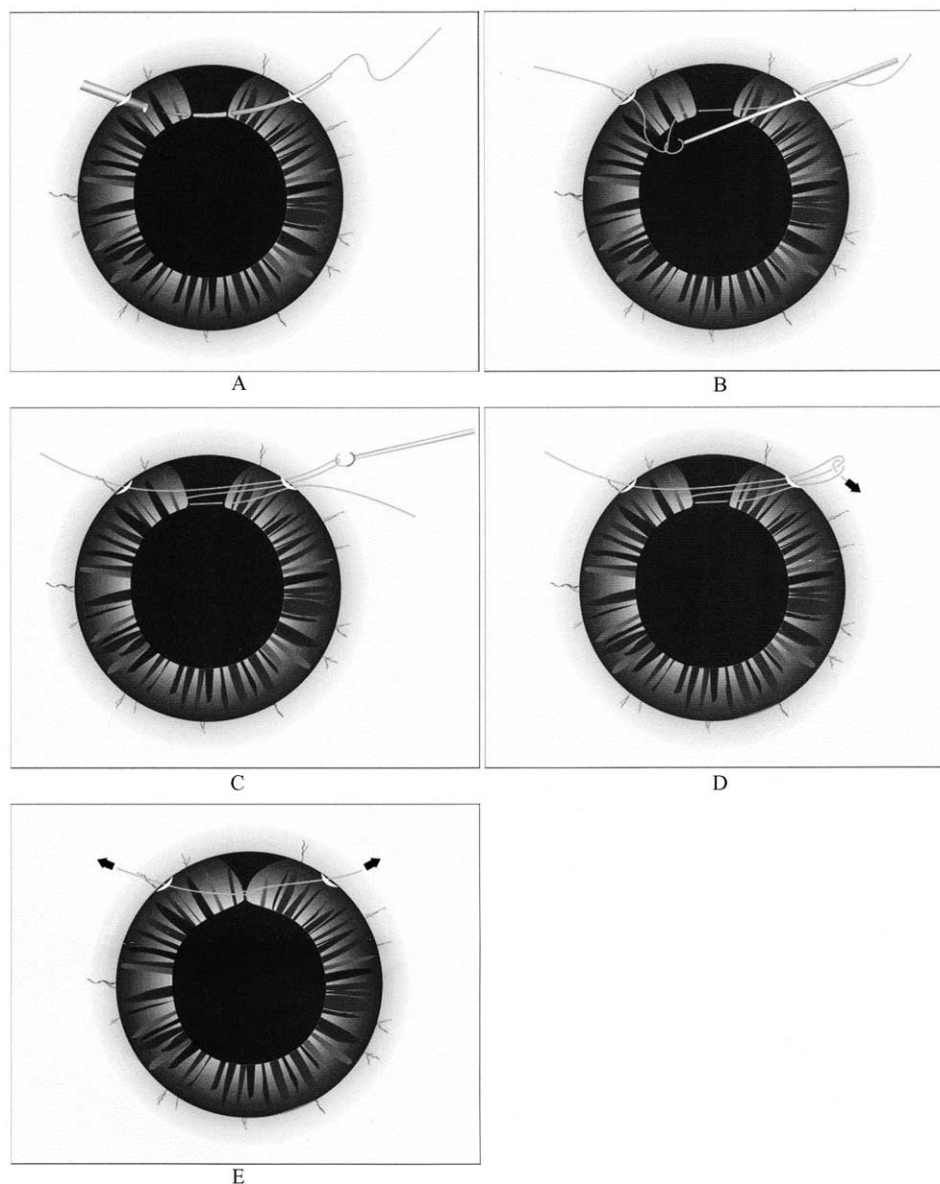


Figure 3. (Chang) Siesper slipknot technique as originally described for repairing an iris defect. Although the free suture end should be passed through the loop twice, only the first of the 2 passes is shown.

iris-fixation of posterior chamber IOLs performed coincident with a penetrating keratoplasty.²⁰⁻²⁴ This may reflect the fact that iris suturing is much easier to perform through an open-sky approach, as compared with limbal incisions.

Navia-Aray²⁵ reported on 30 aphakic eyes in which a secondary posterior chamber IOL was sutured to the iris via a limbal approach. His technique involved placing 4 sutures through the positioning holes in the optic. Parker and Price²⁶ described a technique in which the suture is passed through the edge of a silicone optic. Performed through a limbal incision, this method fixates

the optic rather than the haptic to the iris. More recently, Condon and coauthors reported on a large pooled series of patients with iris-fixated posterior chamber IOLs that were secondarily implanted for aphakia or as part of an IOL exchange (Garry P. Condon, MD, and coauthors, "Iris Fixation of Foldable PC IOLs with Modified McCannel Slipknot Suture," presented at the ASCRS Symposium on Cataract, IOL and Refractive Surgery, San Francisco, California, USA, 2003). The authors also describe the use of the modified Siesper slipknot technique for suturing the haptic to the iris via a limbal approach.

The current series details a slightly different application for this iris-fixation technique from those previously described, namely as a means to reposition and stabilize subluxated posterior chamber IOL. As with secondary posterior chamber IOL implantation, the anatomic goals are the same: a securely centered retropupillary IOL without distortion or functional impairment of the pupil. The advantage of iris fixation in these eyes is the avoidance of scleral suturing or an IOL exchange and the ability to perform the entire procedure through paracentesis-sized limbal incisions. Unlike with secondary posterior chamber IOL implantation, suturing of a single haptic was sufficient to secure most of the malpositioned IOLs in this series.

Compared with an open-sky McCannel technique during penetrating keratoplasty, suturing a haptic to the iris through a limbal approach is technically more challenging. It requires 2 separate but challenging maneuvers: blindly ensnaring the haptic with the iris suture and tying the knot within the anterior chamber. Pupillary capture of the optic, combined with use of the long, curved CIF-4 10-0 Prolene needle, facilitates the first maneuver. The ab interno exit of the needle out through a preplaced paracentesis incision can be difficult. Introducing the viscoelastic cannula ab externo to guide the needle out facilitates this.

Stark and coauthors⁵ describe making an overlying corneal incision to externalize the suture ends and lay down the knot. However, in addition to an additional incision, this requires elevating the ensnared iris and haptic up to the incision as the knot is tightened. This necessitates undesirable displacement of the iris and the IOL.

Siepsler described a slipknot suture for intraocular repair of iris defects (Figure 3) (S. Siepsler, MD, "The Closed-Chamber Slipping Suture Technique for Iris Repair," *EyeWorld*, July 1997, page 3). The advantage of the Siepsler slipknot is that the knot can be tied externally and then slid through a paracentesis opening down onto the haptic without any need to displace it. This permits all maneuvers to be performed through clear corneal stab incisions within a closed chamber with negligible movement of the IOL and iris.

In conclusion, suture fixation of 1 or both haptics can prevent recurrent subluxation of a repositioned posterior chamber IOL. This should be considered if there is insufficient capsular or zonular support or the overall

sulcus diameter is too large for an IOL that is not confined to the capsular bag. Although technically challenging, suturing the haptic(s) to the iris avoids the additional manipulation and drawbacks of scleral suture fixation. The Siepsler slipknot avoids the extra incision and the iris/IOL displacement necessitated by tying the knot externally. Thus, it is ideally suited for accomplishing the closed-chamber, modified McCannel iris suturing technique through paracentesis-sized incisions during IOL repositioning procedures. Unlike secondary IOL implantation, fixation of a single haptic was sufficient to secure the IOL in most cases.

References

1. Hannush SB. Sutured posterior chamber intraocular lenses: indications and procedure. *Curr Opin Ophthalmol* 2000; 11:233-240
2. Dick HB, Augustin AJ. Lens implant selection with absence of capsular support. *Curr Opin Ophthalmol* 2001; 12:47-57
3. Wagoner MD, Cox TA, Ariyasu RG, et al. Intraocular lens implantation in the absence of capsular support: a report by the American Academy of Ophthalmology (Ophthalmic Technology Assessment). *Ophthalmology* 2003; 110:840-859
4. McCannel MA. A retrievable suture idea for anterior uveal problems. *Ophthalmic Surg* 1976; 7(2):98-103
5. Stark WJ, Michels RG, Bruner WE. Management of posteriorly dislocated intraocular lenses. *Ophthalmic Surg* 1980; 11:495-497
6. Chang DF. Viscoelastic levitation of posteriorly dislocated intraocular lenses from the anterior vitreous. *J Cataract Refract Surg* 2002; 28:1515-1519
7. Friedberg MA, Pilkerton AR. A new technique for repositioning and fixating a dislocated intraocular lens. *Arch Ophthalmol* 1992; 110:413-416
8. Thach AB, Dugel PU, Sipperley JO, et al. Outcome of sulcus fixation of dislocated posterior chamber intraocular lenses using temporary externalization of the haptics. *Ophthalmology* 2000; 107:480-484; discussion by WF Mieler, 485
9. Hanemoto T, Ideta H, Kawasaki T. Dislocated intraocular lens fixation using intraocular cowhitch knot. *Am J Ophthalmol* 2001; 131:265-267
10. Lee S-C, Tseng S-H, Cheng H-C, Chen FK. Slipknot for scleral fixation of intraocular lenses. *J Cataract Refract Surg* 2001; 27:662-664
11. Hayashi K, Hayashi H, Nakao F, Hayashi F. Intraocular lens tilt and decentration, anterior chamber depth, and refractive error after trans-scleral suture fixation surgery. *Ophthalmology* 1999; 106:878-882

12. Bourke RD, Gray PJ, Rosen PH, Cooling RJ. Retinal detachment complicating scleral-sutured posterior chamber intraocular lens surgery. *Eye* 1996; 10:501–508
13. Lee J-G, Lee J-H, Chung H. Factors contributing to retinal detachment after transscleral fixation of posterior chamber intraocular lenses. *J Cataract Refract Surg* 1998; 24:697–702
14. Solomon K, Gussler JR, Gussler C, Van Meter WS. Incidence and management of complications of transsclerally sutured posterior chamber lenses. *J Cataract Refract Surg* 1993; 19:488–493
15. Manabe S, Oh H, Amino K, et al. Ultrasound biomicroscopic analysis of posterior chamber intraocular lenses with transscleral sulcus suture. *Ophthalmology* 2000; 107:2172–2178
16. Kuchle M, Seitz B, Hofmann-Rummelt C, Naumann GO. Histopathologic findings in a transsclerally sutured posterior chamber intraocular lens. *J Cataract Refract Surg* 2001; 27:1884–1888
17. Cahane M, Chen V, Avni I. Dislocation of a scleral-fixated, posterior chamber intraocular lens after fixation suture removal. *J Cataract Refract Surg* 1994; 20:186–187
18. Lee S-C, Chen FK, Tseng S-H, Cheng H-C. Repositioning a subluxated sutured intraocular lens in a vitrectomized eye. *J Cataract Refract Surg* 2000; 26:1577–1580
19. Assia EI, Nemet A, Sachs D. Bilateral spontaneous subluxation of scleral-fixated intraocular lenses. *J Cataract Refract Surg* 2002; 28:2214–2216
20. Apple DF, Price FW, Gwin T, et al. Sutured retropupillary posterior chamber intraocular lenses for exchange or secondary implantation; The 12th Annual Binkhorst Lecture, 1988. *Ophthalmology* 1989; 96:1241–1247
21. Price FW Jr, Whitson WE. Visual results of suture-fixated posterior chamber lenses during penetrating keratoplasty. *Ophthalmology* 1989; 96:1234–1239; discussion by RF Skinert, 1239–1240
22. Busin M, Brauweiler P, Böker T, Spitznas M. Complications of sulcus-supported intraocular lenses with iris sutures, implanted during penetrating keratoplasty after intracapsular cataract extraction. *Ophthalmology* 1990; 97:401–405; discussion by RF Meyer, 405–406
23. Gaster RN, Ong HV. Results of penetrating keratoplasty with posterior chamber intraocular lens implantation in the absence of a lens capsule. *Cornea* 1991; 10:498–506
24. Zeh WG, Price FW Jr. Iris fixation of posterior chamber intraocular lenses. *J Cataract Refract Surg*. 2000; 26:1028–1034
25. Navia-Aray EA. Suturing a posterior chamber intraocular lens to the iris through limbal incisions: results in 30 eyes. *J Refract Corneal Surg* 1994; 10:565–570
26. Parker DS, Price FW Jr. Suture fixation of posterior chamber intraocular lens in anticoagulated patients. *J Cataract Refract Surg* 2003; 29:949–954