



ModernMedicine ModernMedicine Community

Welcome back, Dr. Chang [Edit Your Profile](#) / [Log Out](#)

 ModernMedicine Recommended Medical Sites

[Home](#) [Clinical Perspectives](#) [Business Perspectives](#) [Patient Care](#) [Learning](#) [Community](#) [Products](#) [Careers](#) [About Us](#)
HOT TOPICS: [Cardiometabolic Disorders & Weight](#) · [Liability & Risk Management](#) · [Health Care IT](#)
 [E-mail Alerts](#) [RSS Feeds](#)

Severity determines intraoperative floppy iris syndrome management approach

Options include use of OVD, intracameral drugs, iris retractors, pupil expansion device

Publish date: Nov 1, 2008

By: Lynda Charters

[Email](#) | [Print](#) | [Share](#) | [Save](#) | [License](#)
Ophthalmology Times

- The management of intraoperative floppy iris syndrome (IFIS) resulting from use of alpha-1 antagonists such as tamsulosin (Flomax, Boehringer Ingelheim) can be approached in one of several different ways depending on its severity.
- Strategies include the use of an ophthalmic viscosurgical device (OVD), intracameral epinephrine, iris retractors, or pupil expansion rings, or a combination of several techniques, such as the use of an OVD and intracameral epinephrine.



Hong Kong—The management of intraoperative floppy iris syndrome (IFIS) resulting from the use of alpha-1 antagonists such as tamsulosin (Flomax, Boehringer Ingelheim) can be approached in one of many different ways depending on its severity, according to David F. Chang, MD, who described his approach at the World Ophthalmology Congress.

Dr. Chang, clinical professor of ophthalmology at the University of California, San Francisco, and in private practice in Los Altos, CA, reviewed different strategies including the use of a viscoadaptive ophthalmic viscosurgical device (OVD), intracameral epinephrine, iris retractors, and pupil expansion devices.

Dr. Chang has no financial interests relevant to this report.
E-mail: dceye@earthlink.net

"When considering the management of IFIS, we must recognize that there is a wide range of severity among different patients taking tamsulosin and other alpha blockers," he said. "This means that a technique that works beautifully on one patient may not work on the next, which is why it is helpful to be adept at multiple strategies that can be used individually or in combination."

Mild IFIS is characterized by billowing of the iris alone, moderate IFIS includes iris billowing and intraoperative miosis, and severe IFIS is marked by the presence of all three classic signs, including iris prolapse, Dr. Chang said.

He recounted a multicenter prospective study that included 167 eyes of patients taking tamsulosin and undergoing cataract surgery. In that study, nine out of 10 eyes had IFIS of at least mild severity, and three out of four eyes had moderate to severe IFIS.

Management strategies

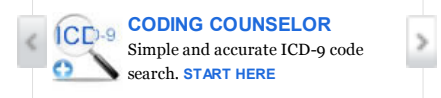
The first approach that Dr. Chang described, use of a highly retentive and viscoadaptive OVD, such as 2.3% sodium hyaluronate (Healon 5, Advanced Medical Optics), provides expanded pupillary dilation in patients with moderate-sized pupils, as he demonstrated in a video of a mild case of IFIS. For this strategy to be successful, one must use lower aspiration flow and vacuum settings on phacoemulsification equipment and be reasonably experienced with using this OVD, he said.

"As more [OVD] exits the eye, the floppy iris will constrict, requiring additional replenishment," Dr. Chang said. "This technique works best with reasonably large pupils and with softer nuclei, where you do not need high vacuum to optimize holding power," he added.

Dr. Chang also presented a video case of a patient who had stopped taking tamsulosin 18 months previously. After capsulorrhexis was performed and the phaco tip was inserted, the iris immediately began to billow and prolapsed to the phaco incision. After intracameral epinephrine



Practice Tools



POPULAR ARTICLES

[Weight-based dosing: Extended-release minocycline efficient, predictable](#)

[FDA warns Allergan on Aczone promotion](#)


[Exit Accutane: Derms' reactions mixed as Roche pulls long-standing remedy](#)

[Gaining control: Birth control pills, spironolactone first-line treatments for hormonal acne](#)

[Getting to the root: Look below the surface for cause of hyperandrogenic symptoms](#)

MORE POPULAR ARTICLES

Featured Jobs


[More Jobs](#)

SPONSORED MEDIA

[OTLA Video Player](#)

[Multimedia: Why Patients Considering an IUC](#)

1:4000 (mixing 0.2 ml of 1:1000 bisulfite-free epinephrine with 0.6 ml of balanced salt solution in a 3-ml syringe) was injected, the pupil quickly dilated wider. Just as impressively, he said, the iris became more rigid, without any tendency for billowing or prolapse, and the rest of the case proceeded without any difficulty.

"This is a wonderful rescue technique, because it is more difficult to safely place iris retractors following the capsulorrhexis and hydrodissection," Dr. Chang stated. "Intracameral epinephrine is well tolerated, and for patients taking alpha blockers, there is no harm in trying it intraoperatively. While it might not always dilate the pupil further, it will at least increase iris rigidity in many cases. You can always combine [the 2.3% sodium hyaluronate OVD] with epinephrine to widen the pupil further for the capsulorrhexis step."

Patients taking tamsulosin who have pupils that dilate very poorly usually will have severe IFIS, according to Dr. Chang. "In these cases, I go straight to mechanical devices, such as iris retractors," he said.

1 2 [Next »](#)

POST A COMMENT

Please complete the form below to post your comment.

Bold = Required

Email Address _____ Your email address will NOT be published.

Display Name _____ appears with your comment

City _____

State _____

Country _____

Remember me: Yes No

Comment _____ read our [privacy policy](#)

Note: does not support HTML
All comments submitted are subject to review, and may be delayed before posting. We reserve the right not to post comments.

[Submit Now >>](#)

LATEST PRACTICE NEWS

[Rural Residents More Likely to Have Total Joint Replacement](#)

[Uninsured Show Higher Risk for Death Following Trauma](#)

[Medicaid Enrollment Common Among Overdose Deaths](#)

[Uninsured Children May Be More Likely to Die in the Hospital](#)

[SNS: Web Surfing Linked to Brain Function in Older Adults](#)

[_ More](#)

LATEST DRUG NEWS

[Cetuximab Linked to Resection of Liver Metastases](#)

[H1N1 Influenza Rates Drop in Many States](#)

[Zegerid OTC Approved for Frequent Heartburn](#)

[Observing Antiretroviral Therapy Yields Little Benefit](#)

[Morphologic Changes Gauge Liver Cancer Therapy Response](#)

[_ More](#)

Clinical Perspectives

Acne
Adolescent Medicine
Allergy & Immunology
Alzheimer's Disease
Asthma
BPH
Breast Cancer
Cardiology

Business Perspectives

Coding Counselor
Liability & Risk Management
Health Care Information Technology
Practice Management
Business Operations
Human Resources
Health Law & Policy

Popular Topics

CME/CE
Coding Counselor
eNewsletters
Patient Education Center
Blogs
Discussions
ModernMedicine Radio
Surveillance

[May Say YES to ParaGard](#)

SPONSORED

[sponsored multimedia Promiseb A non steroidal topical cream for managing seborrheic dermatitis](#)

[MORE MEDIA](#)



ModernMedicine

Bringing together Advanstar's trusted healthcare journals along with powerful tools, resource, decision support and advisory functions



[Home](#) | [About Us](#) | [ModernMedicine Team](#) | [Editorial and Advertising Policy](#) | [Our Publications](#) | [Terms & Conditions](#) | [Contact Us](#) | [Medical News](#) | [Medical Articles](#) | [CME Center](#) | [Patient Education](#) | [Practice Management](#) | [All Content](#) | [Privacy Policy](#) | [Terms of Use](#) | [Linking and RSS Policy](#)

© 2009 Advanstar Communications, Inc. All rights reserved.
Reproduction in whole or in part is prohibited.
Please send any technical comments or questions to our webmaster.