

# Floppy iris syndrome requires special management

Cheryl Guttman  
in Washington, DC

CATARACT surgeons should ask patients about past or current treatment with tamsulosin (Flomax, Boehringer Ingelheim) and learn appropriate strategies for managing intraoperative floppy iris syndrome (IFIS) sometimes associated with its use, said David F. Chang MD, at the annual ASCRS Symposium on Cataract, IOL, and Refractive Surgery.

IFIS associated with tamsulosin use is characterised by a triad of signs. These are initial billowing and floppiness of the iris in response to normal irrigation currents in the anterior chamber; repeated iris prolapse to the incisions; and progressive miosis. Often, but not always, the pupil dilates poorly to begin with, said Dr Chang, clinical professor, University of California, San Francisco.



David Chang

from a consecutive series of 900 eyes of 741 patients in whom he performed cataract surgery without knowledge of their medication history. IFIS occurred in 21 (2%) eyes of 16 (2%) patients. Of the 16 affected patients, subsequent questioning revealed that 15 were currently

**“To prevent complications caused by iris prolapse and progressive miosis, surgeons should use alternative small pupil management strategies,”**

“While there are certainly other causes of iris prolapse and intraoperative miosis, it is the combination of these three signs that defines IFIS. Awareness of this new syndrome is important because the usual pupil stretching techniques will be ineffective for IFIS. Therefore, to prevent complications caused by iris prolapse and progressive miosis, surgeons should use alternative small pupil management strategies,” he emphasised.

Dr Chang credited John R. Campbell MD for first suspecting a link between tamsulosin and floppy irides. To test this hypothesis, Dr Campbell conducted a retrospective study that included all cataract surgery procedures performed in his two-surgeon practice during 2003.

The series included 706 eyes of 511 patients. Review of the operative reports identified IFIS in 16 (2%) eyes and 10 (2%) patients, all of who were on tamsulosin. An additional six patients were also identified who were using tamsulosin but did not have any mention of floppy irides in their operative report.

In order to better characterise this syndrome and look for causative factors, Dr Chang performed a masked prospective investigation. He analysed data

on or had previously taken tamsulosin. None of the 725 patients who did not develop IFIS were using tamsulosin.

Analyses based on pooled data from both studies showed iris colour and history of pseudoexfoliation or diabetes had no effect on risk of IFIS.

In the retrospective study, posterior capsule rupture occurred in two (12.5%) of the 16 cases that experienced IFIS. Several of the IFIS patients in the two series also had a history of posterior capsule rupture in the fellow (non-study) eye during prior contralateral surgery.

## What is an appropriate treatment method?

Discussing management, Dr Chang noted that the common pupil stretching techniques – even if augmented with partial thickness sphincterotomies – are totally ineffective for expanding or maintaining the pupil diameter in IFIS. Instead, mechanical restraint of the pupil using an expansion ring or iris hooks offers a better method to hold the pupil open and keep the iris from prolapsing.

These devices should ideally be placed before capsulorhexis creation. Dr Chang recommended that when using iris hooks they should be

inserted in the diamond pattern described by Thomas Oetting MD. This configuration, where one hook is underneath the tunnelled corneal incision, affords better exposure in front of the phaco tip and avoids upward tenting of the iris in front of the phaco incision.

Use of the highly viscous, retentive ophthalmic viscosurgical device Healon 5 (AMO) offers another alternative for mechanically dilating the pupil and blocking iris prolapse to the incision. However, it may be best suited in cases where the pupil is relatively well dilated preoperatively. If one is not planning to use iris hooks or expansion rings, consideration should be given to having patients discontinue their tamsulosin for a week or two preoperatively, Dr Chang said.

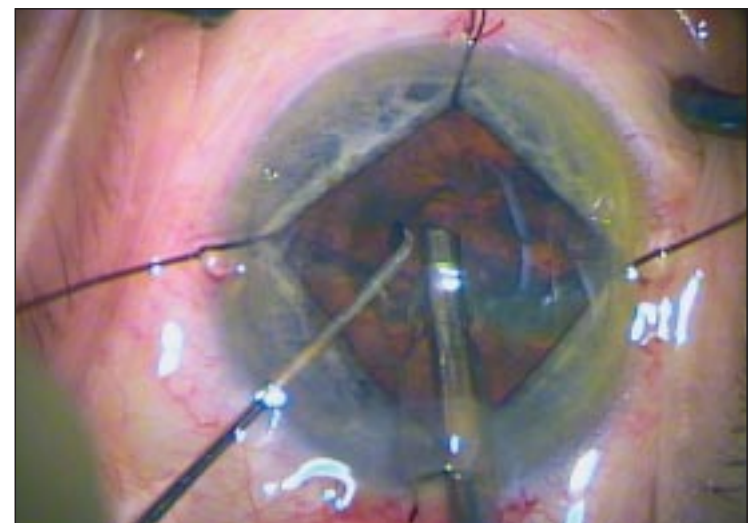
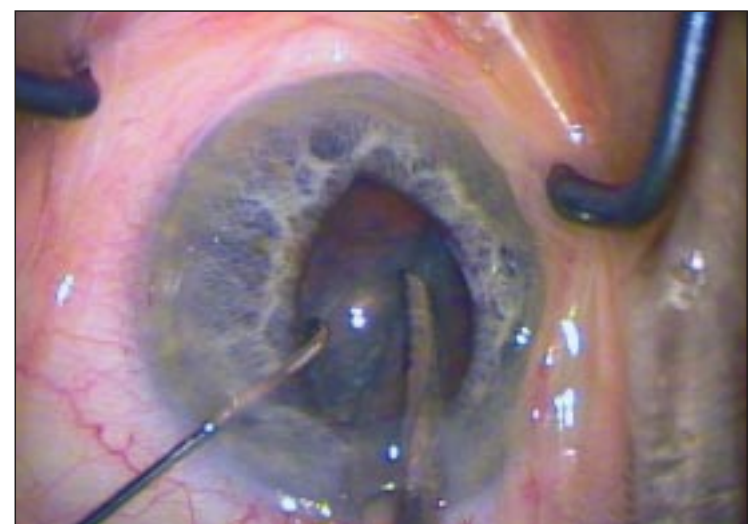
Surgeons who attempt to use Healon 5 as a viscodilator should also be aware that they will need to use low aspiration flow and vacuum settings to prevent immediate evacuation of the Healon 5 from the anterior chamber.

“Healon 5 is a useful adjunct as long as it stays in the eye, but even with low flow and vacuum it may be necessary to replenish the Healon 5 at multiple times during the procedure. For surgeons not experienced with Healon 5 and low flow techniques, iris retractors or placement of an expansion ring probably provide more reliable methods for maintaining a large pupil diameter during surgery in eyes with IFIS,” Dr Chang said.

Dr Chang also reported that bimanual microincisional phaco may help to some degree, because of the more tightly sized incisions and the ability to better direct the irrigation flow anterior to the iris plane. However, if the pupil is already small, the iris still tends to billow and prolapse with this approach as well.

## Possible mechanism

The development of IFIS in patients treated with tamsulosin relates to that drug’s activity as an alpha 1A- selective adrenoceptor antagonist. Three different subtypes of the alpha 1 receptor have been described – the alpha 1A subtype that is blocked by tamsulosin is the predominant subtype found in the bladder neck and prostate, and tamsulosin is indicated for the treatment of the signs and symptoms of benign prostatic hyperplasia (BPH) because it relaxes smooth muscle in those tissues to improve urinary outflow. Based on its effects in the bladder, tamsulosin is also



When using iris hooks they should be inserted in the diamond pattern described by Thomas Oetting MD.

Courtesy of David Chang MD

being used off-label to treat female urinary retention associated with bladder neck obstruction.

However, results of animal studies show that the alpha 1A receptor is also the predominant subtype in the iris dilator smooth muscle where it mediates contraction.

“From a pharmacological perspective, there is a perfect correlation between treatment with tamsulosin and the development of IFIS. Other alpha 1 adrenoceptor antagonists that are not selective for the 1A receptor subtype did not appear to be associated with IFIS in the retrospective study. In Dr Campbell’s retrospective chart review, there were 11 patients using either doxazosin (Cardura, Pfizer), terazosin (Hytrin, Abbott), or prazosin (Minipress Pfizer) who did not have any mention of floppy irides in the operative report,” Dr Chang said.

Since IFIS has occurred in patients who have been withdrawn from tamsulosin treatment for periods of weeks to as long as several years, it appears that the drug may cause

some degree of semi-permanent atrophy and loss of muscle tone. How long the drug must be used before patients become at risk for IFIS is not known, although there is some evidence that IFIS can appear after only a few weeks on the drug, Dr Chang said.

Is IFIS enough of a reason to avoid prescribing tamsulosin altogether? Dr Chang does not feel that this is the case.

“There are some excellent methods for managing the small pupil in tamsulosin patients. The key is that the surgeon can now anticipate when IFIS will occur,” he said.

“We have started a multicentre study to prospectively assess the complication rate in tamsulosin patients where the surgeon is able to anticipate IFIS and therefore use one of the recommended management strategies,” Dr Chang added.

Dr Chang’s presentation was awarded the best paper of session at the ASCRS meeting, and the related video received first place in the Cataract Complications category of the ASCRS Film Festival.

dceye@earthlink.net