

# Surgical Placement of an Optical Prosthetic Device for End-Stage Macular Degeneration

## *The Implantable Miniature Telescope*

Kathryn A. Colby, MD, PhD; David F. Chang, MD; R. Doyle Stulting, MD, PhD; Stephen S. Lane, MD

**Objective:** To describe the surgical procedure for placement of an implantable telescope prosthesis for end-stage age-related macular degeneration.

**Methods:** As part of a phase 2/3 clinical trial for patients with bilateral, irreversible age-related macular degeneration, the optimal procedure for monocular placement of the telescope prosthesis was determined.

**Results:** Because of the unique configuration of the tele-

scope prosthesis, proper wound construction, anterior chamber management, and device insertion after phacoemulsification are critical for successful surgery.

**Conclusion:** A unique surgical technique ensures appropriate placement of the telescope prosthesis, while reducing surgical trauma to the corneal endothelium.

*Arch Ophthalmol.* 2007;125(8):1118-1121

**A**N IMPLANTABLE TELESCOPE prosthetic device for end-stage age-related macular degeneration was recently studied in a multicenter phase 2/3 clinical trial. In this trial, 206 patients received the telescope prosthesis implant. One-year outcomes showed that 67% of eyes with the implant achieved a 3-line or greater improvement in best-corrected distance visual acuity compared with 13% of the fellow eye in control patients ( $P < .001$ ).<sup>1</sup> Meaningful improvements in quality of life measures were also shown.

The configuration and the special surgical techniques required by the device for proper implantation of the device make the procedure challenging, even for surgeons experienced in anterior segment procedures. Although postoperative endothelial cell density (ECD) stabilizes with time, initial cell loss caused by implantation can be significant.<sup>1,2</sup> Based on our experience with the clinical trial, we describe the recommended surgical technique to ensure proper device placement while minimizing endothelial damage.

### DEVICE CONFIGURATION

This visual prosthetic device is a compound telescope system that consists of a glass cylinder (4.4 mm in length and 3.6

mm in diameter) housing wide-angle micro-optics. The cylinder is held in a 1-piece polymethylmethacrylate carrier with 2 rigid polymethylmethacrylate haptics (**Figure 1**). In conjunction with the cornea, the device functions as a telephoto system, rendering an enlarged retinal image to reduce the relative size of the scotoma. It is designed for monocular implantation in phakic eyes with poor central vision.

The height of the glass cylinder approximates that of 13 stacked intraocular lenses (IOLs). The device is heavier (115 mg in air and 60 mg in aqueous) and the carrier haptics are less flexible than those found on 1-piece polymethylmethacrylate IOLs. The implantable telescope protrudes 0.1 to 0.5 mm through the pupillary plane (**Figure 2**), leaving a minimum of 2.0 mm of corneal clearance (**Figure 3**). When the telescope prosthesis is properly implanted in eyes with anterior chamber depths of 2.5 mm or more, the face of the optic should not touch the corneal endothelium.

### ENDOTHELIAL CELL LOSS

Telescope implantation was associated with a 13% decrease in ECD at 12 months in the phase 1 trial, in which only 4 surgeons implanted the device.<sup>3</sup> In the phase 2/3 trial involving 32 surgeons, endothe-

**Author Affiliations:**  
Massachusetts Eye and Ear Infirmary, Department of Ophthalmology, Harvard Medical School, Boston (Dr Colby); Department of Ophthalmology, University of California, San Francisco (Dr Chang); Emory Vision Center, Emory University, Atlanta, Georgia (Dr Stulting); and Associated Eye Care, Stillwater, Minnesota (Dr Lane).

lial cell loss at 12 months averaged 25%, which was higher than the cell loss seen after phacoemulsification<sup>4,5</sup> but comparable with that seen after large-incision cataract extraction.<sup>6,7</sup>

Most of the ECD loss occurred in the initial postoperative period (20% reduction in ECD by 3 months). Endothelial cell density stabilized with time, suggesting that the endothelial cell loss is a result of surgery rather than contact with the device or inflammation.

Two cases of corneal decompensation required corneal transplantation. In both cases, the surgeon encountered positive vitreous pressure, iris prolapse, and anterior chamber shallowing during surgery. In 1 of the cases, 1 haptic was placed in the capsular bag and the other in the ciliary sulcus.

### SURGICAL PROCEDURE

The implantation procedure for the telescope prosthesis differs significantly from standard IOL implantation. Phacoemulsification with foldable IOL implantation is typically performed through a small ( $\leq 3$ -mm), self-sealing incision. The telescope is not foldable and cannot be injected. Its larger dimensions require a much larger incision (12-mm). This increases the surgical time and necessitates the use of sutures and a retrobulbar block. The telescope prosthesis can only be implanted in the capsular bag. Sulcus implantation is not an option. A large capsulorrhexis of at least 7-mm diameter is required for telescope implantation. While a standard IOL can be implanted through a smaller capsulorrhexis or in the presence of an anterior capsular tear, such conditions preclude implantation of the telescope prosthesis. Appropriate selection and use of ophthalmic viscoelastic devices (OVDs) is far more critical during implantation of the telescope than during a standard IOL implantation. In addition, the anatomic fit of the telescope in the capsular bag makes removal of the OVD more challenging than usual. After surgery, extended monitoring is required to prevent wound complications and to manage suture-induced astigmatism and inflammation.

We describe the recommended surgical procedure for implantation of the telescope in 4 steps: wound construction, lens extraction, telescope implantation, and wound closure.

### WOUND CONSTRUCTION

An incision of at least 12-mm arc length is required to provide sufficient vertical clearance for telescope implantation without undue trauma to the corneal endothelium.

A large conjunctival peritomy is performed. A partial-thickness (50%) vertical groove of at least 12-mm arc length is created at the limbus with a crescent blade, which can then be used to create a short (0.5-mm) horizontal plane along the entire length of the groove. This results in a biplanar wound that facilitates alignment during closure. An anterior limbal incision is preferable to a more posterior one because the device must be directed posteriorly into the capsular bag and an anterior wound allows the widest opening for any given incision arc length.

### LENS EXTRACTION

A keratome is used to enter the anterior chamber through the groove; the OVD is then injected. We used a "soft-shell" technique,<sup>8</sup> in which the endothelium is coated with a dispersive OVD (such as Viscoat; Alcon, Fort Worth, Texas) and the anterior chamber is filled with a cohesive OVD (such as Healon; Advanced Medical Optics, Santa Ana, California), with excellent success.

A large capsulorrhexis ( $\geq 7$  mm) is created. An intact capsulorrhexis and capsular bag and normal zonular integrity are necessary to securely place the telescope prosthesis. Forcing the inflexible device through a smaller capsulorrhexis increases the likelihood of tearing the anterior capsule or creating a zonular dialysis.

Surgeons may use their preferred phacoemulsification method. Complete cortical removal reduces postoperative inflammation and subsequent posterior capsular opacification. Thorough cortical cleanup is



Figure 1. Implantable telescope prosthesis.

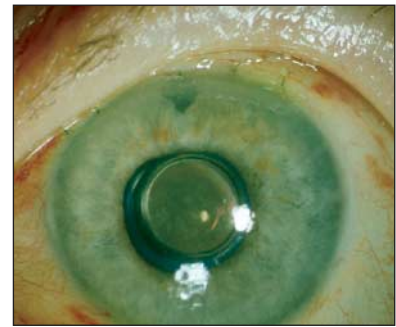


Figure 2. Clinical appearance of a telescope-implanted eye 1 day after implantation.

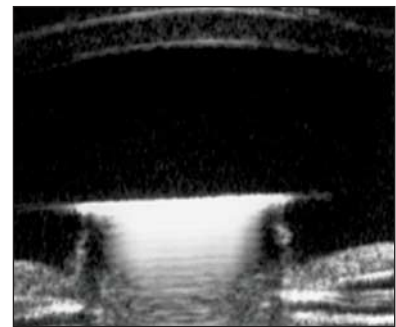
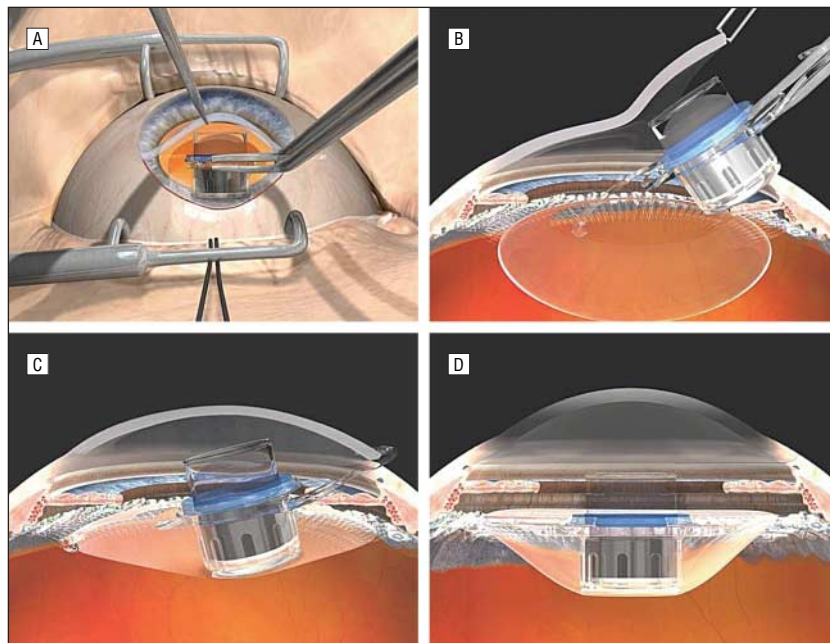


Figure 3. Ultrasonic biomicroscopy of the same patient as in Figure 2 performed 3 years after telescope implantation. The distance between the corneal endothelium and the front window of the device is 2.3 mm.

also important to prevent residual cortex from becoming trapped between the posterior window of the device and the posterior capsule. Although capsule polishing can also be incorporated at this stage, extreme care should be used to avoid damaging the capsule.

The telescope prosthesis should not be implanted if there is an anterior or a posterior capsular tear. A conventional posterior or anterior chamber IOL should be placed in this instance. Visual acuity results from 11 cases treated in this manner in the clinical trial showed no significant change from baseline.<sup>1</sup>



**Figure 4.** Telescope implantation procedure. A, Cornea is elevated to allow for atraumatic insertion of the telescope prosthesis (surgeon's view). Note large incision size. B, Side view demonstrating the optimal angle of insertion. Note the degree of corneal elevation necessary for the telescope optic to be inserted with minimal damage to the endothelium. The front of the telescope is liberally coated with a dispersive viscoelastic material to prevent damage to the corneal endothelium in case of inadvertent contact. The capsular bag and anterior chamber have been inflated with a viscoadaptive ophthalmic viscoelastic device to prevent collapse (and endothelial contact) during telescope insertion. C, Leading haptic and telescope in the capsular bag. Bimanual rotation is required to place the trailing haptic into the capsular bag. A large capsulorrhexis facilitates proper placement of the trailing haptic. D, Final position of the telescope with both haptics in the lens capsule. Note the amount of protrusion above the pupillary plane.

### TELESCOPE IMPLANTATION

The internal lip of the wound is opened along the entire extent of the groove using a blade or scissors. The anterior chamber and capsular bag are filled with a cohesive OVD such as Healon or Healon V. The optic and leading haptic of the telescope prosthesis should be liberally coated with a dispersive OVD to prevent damage to the endothelium should inadvertent contact with the cornea occur. Healon V is too thick to adequately spread over the prosthesis for this purpose.

Using the dominant hand, the surgeon grasps the carrier plate of the telescope with forceps or a lens inserter, taking care not to touch the face of the optic. With the other hand, or with the assistance of an experienced surgical technician, the corneal lip is elevated with 0.12-mm forceps and the telescope is placed into the eye.

During insertion, the gaping of the large incision, combined with pressure on the posterior scleral lip, will cause the OVD to "burp" out of the anterior chamber. Therefore, ad-

equate clearance must be maintained between the top of the device and the cornea.

The cornea is lifted to maximize the opening (but without causing tenting of the cornea) and a steep 45° entry angle is required to place the leading haptic in the capsular bag. Exaggerated lift of the cornea can cause the endothelium to contact the front edge of the telescope, but insufficient separation will allow the device to touch the endothelium (**Figure 4**). Once the cornea is lifted, it is important to implant the telescope prosthesis using a brisk and decisive motion. If one attempts to do this in "slow motion," too much of the OVD will escape and the anterior chamber will collapse. The intermediate goal is to have the carrier plate entirely within the anterior chamber in the pupillary plane with the leading haptic inside the capsular bag. A cyclodialysis spatula can be used in the nondominant hand to help direct the leading haptic downward through the capsulorrhexis and into the capsular bag, but this requires an experienced assistant to lift the cornea.

Once the leading haptic is in the capsule and the optic is in the eye, the surgeon can release both the cornea and the carrier plate and can place additional dispersive OVD over the top of the optic tube to prevent endothelial contact.

The telescope prosthesis is too stiff to be dialed or dunked into the bag as can be done with a standard polymethylmethacrylate IOL. Instead, bimanual rotation using 2 instruments simultaneously must be performed. Two Sinsky or Kuglen hooks are placed in the eye. The superior hook compresses the trailing haptic against the optic without placing undue pressure on the inferior capsule. The inferior hook is placed between the leading haptic that is already in the bag and the carrier plate. Both hooks are rotated simultaneously allowing atraumatic implantation of the trailing haptic. The capsular bag should be well inflated for this step. Viscoelastic material lost during the initial stages of implantation must be replaced before the trailing haptic is inserted into the capsular bag. Once both haptics are in the capsule, the telescope prosthesis is rotated so that the haptics are located at the 6- and 12-o'clock positions for maximum stability of the device.

### WOUND CLOSURE

The incision is closed with 10.0 nylon sutures. Meticulous removal of the OVD is essential to prevent postoperative increases in intraocular pressure. Bimanual irrigation and aspiration are particularly useful, because the sleeveless bimanual aspirating tip can reach the intracapsular OVD located behind the carrier plate of the telescope. After the OVD is removed, the pupil is constricted using an intraocular miotic, and a peripheral iridectomy is performed. A sub-Tenon injection of corticosteroid is given (eg, 50 to 100 mg of methylprednisolone sodium succinate or 8 to 16 mg of dexamethasone sodium phosphate) and topical diclofenac sodium is applied. Oral acetazolamide can be given to prevent a postoperative pressure elevation, especially if any viscoelastic material is retained.

## POSTOPERATIVE TREATMENT

Patients require prolonged postoperative education and monitoring and are typically seen 1 day, 1 week, 1 month, and 3 months after the procedure. A longer anti-inflammatory medication regimen and prolonged cycloplegia are necessary. Postoperative medications include a topical antibiotic, prednisolone acetate, 1%, every 2 hours for the first 2 weeks, then tapering off in approximately 3 months, and a topical nonsteroidal agent 4 times daily for the first week. Cycloplegia (with homatropine hydrobromide or atropine sulfate) is important after surgery because contact between the pupil margin and the glass cylinder can result in inflammation, synechiae, and inflammatory deposits on the prosthesis. Sutures can be selectively removed 6 to 8 weeks after surgery in cases with excessive astigmatism. Visual rehabilitation can usually begin 2 to 3 weeks after surgery. Postoperative refractive errors are corrected with spectacles.

## COMMENT

The implantable telescope has completed 2 years of follow-up in a pivotal trial. Visual acuity and quality of life of patients improved significantly; however, surgical implantation of this device is challenging.

It is critical that surgeons not view this first-of-a-kind device simply as a larger IOL. The unique configuration and material composition of the telescope prosthesis demand careful attention to the relationship between the device and the anterior segment throughout the implantation procedure. Surgeons should antici-

pate a learning curve, albeit a short one. In the IMT-002 clinical trial on the implantable telescope,<sup>1</sup> fourth or later surgeries performed by surgeons showed an average 24% ECD loss 2 years after surgery compared with an average 32% ECD loss for their first 3 cases ( $P = .01$ ). In this trial, the rate of ECD loss was lowest in eyes in which the implants were placed by cornea subspecialists.

Surgical trauma to the corneal endothelium can be minimized with the techniques we have described in this article. Specifically, one must create an adequately large incision at the limbus, use an appropriately steep downward entry angle to avoid corneal touch, and make a large-diameter ( $\geq 7$ -mm) capsulorrhexis to accommodate the stiff haptics of the carrier plate with minimal intraoperative manipulation. Meticulous attention should be paid to surgical detail to avoid iris prolapse and a flat anterior chamber. Finally, liberal use of several different types of OVDs is needed to facilitate atraumatic placement.

As detailed previously,<sup>1</sup> this procedure is part of the rehabilitative process in a multidisciplinary approach designed to improve the vision-related quality of life of patients with end-stage age-related macular degeneration. Appropriate surgical management of this device will increase the likelihood of a successful outcome for such patients with few other options.

**Submitted for Publication:** December 7, 2006; final revision received March 14, 2007; accepted March 23, 2007.

**Correspondence:** Kathryn A. Colby, MD, PhD, Massachusetts Eye and Ear

Infirmery, 243 Charles St, Ste 808, Boston, MA 02114 (kacolby@meei.harvard.edu).

**Author Contributions:** Dr Colby had full access to all of the data in the study and takes responsibility for the integrity of the data and the accuracy of the data analysis.

**Financial Disclosure:** All authors served as investigators in the IMT-002 clinical trial sponsored by VisionCare Ophthalmic Technologies Inc, Saratoga, California. Dr Lane also served as the medical monitor for this trial. Drs Lane and Stulting serve on the medical advisory board for the study sponsor as consultants.

## REFERENCES

1. Hudson HL, Lane SS, Heier JS, et al. Implantable miniature telescope for the treatment of visual acuity loss resulting from end-stage age-related macular degeneration: 1-year results. *Ophthalmology*. 2006;113(11):1987-2001.
2. Lane SS, Kuppermann BD. The implantable miniature telescope for macular degeneration. *Curr Opin Ophthalmol*. 2006;17(1):94-98.
3. Lane SS, Kuppermann BD, Fine IH, et al. A prospective multicenter clinical trial to evaluate the safety and effectiveness of the implantable miniature telescope. *Am J Ophthalmol*. 2004;137(6):993-1001.
4. Beltrame G, Salvetat ML, Driussi G, Chizzolini M. Effect of incision size and site on corneal endothelial changes in cataract surgery. *J Cataract Refract Surg*. 2002;28(1):118-125.
5. Bourne RR, Minassian DC, Dart JK, Rosen P, Kaushal S, Wingate N. Effect of cataract surgery on the corneal endothelium. *Ophthalmology*. 2004;111(4):679-685.
6. Kraff MC, Sanders DR, Lieberman HL. Specular microscopy in cataract and intraocular lens patients: a report of 564 cases. *Arch Ophthalmol*. 1980;98(10):1782-1784.
7. Bourne WM, Nelson LR, Hodge DO. Continued endothelial cell loss ten years after lens implantation. *Ophthalmology*. 1994;101(6):1014-1023.
8. Arshinoff SA. Dispersive-cohesive viscoelastic soft shell technique. *J Cataract Refract Surg*. 1999;25(2):167-173.