

consultation section

cataract surgical problem

edited by Samuel Masket, MD

A healthy 25-year-old man with congenital ectopic pupils and crystalline lenses (ectopia lentis et pupillae) had lensectomy with pupillary enlargement in the left eye at age 12 years; the right eye has had no surgery to date. Although the patient wears contact lenses, he has significant complaints of reduced visual function in each eye caused by glare disability and drives at night only with extreme difficulty. He has a strong desire for improved visual function.

Ocular examination demonstrated the following findings: a best corrected visual acuity with contact lenses of 20/60 (phakic or aphakic) in the right eye and 20/50 (aphakic) in the left eye. The potential acuity meter (PAM) showed 20/25 and 20/30, respectively. The intraocular pressure (IOP) is 22 mm Hg in the right eye and 21 mm Hg in the left eye.

Anterior segment evaluation of the right eye (Figure 1) shows a healthy, clear cornea with a deep chamber angle. The pupil is irregular and displaced superotemporally. With maximum pupil dilation, the crystalline lens is noted to be subluxated nasally, with the temporal edge of the lens visible in the midpupil (Figures 2 and 3). As a result, the visual axis passes near the edge of the crystalline lens, producing significant lenticular astigmatism and creating both a phakic and an aphakic optical pathway. Through the phakic optical path, there is refractive astigmatism of 4.50 diopters (D) at axis 40, whereas keratometry reveals 1.75 D of cylinder at 175 degrees. No phacodonesis is visible.

Similarly, the left eye has a healthy, clear cornea with a deep anterior chamber. As seen in Figure 4, the pupil has been altered surgically and is enlarged vertically. Following pharmacologic dilation, a very narrow remnant of capsule is noted inferotemporally, but it is not possible to determine the presence of capsule elsewhere. No vitreous is visible in the anterior segment.

Posterior segment examination of each eye is unremarkable, with a cup-to-disc ratio of 0.1, normal macular regions, and normal peripheral retinal architecture.

Given the patient's strong motivation for improved visual function and the constellation of findings, how would you manage his problem?

■ One should first ascertain which eye has the most glare disability at night. Assuming it is the right eye, lens removal is a reasonable option given the problems

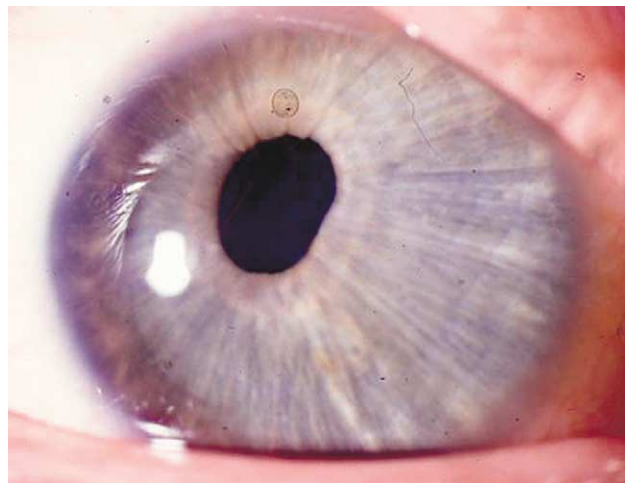


Figure 1. (Masket) The right eye has an irregular and a temporally displaced pupil.

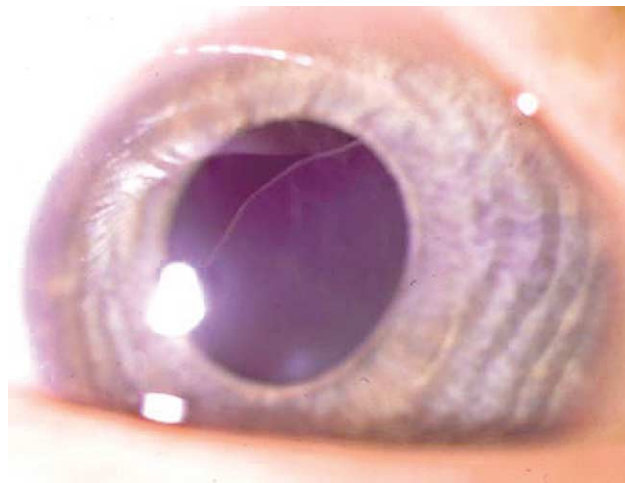


Figure 2. (Masket) The pupil in the right eye dilates poorly; however, the temporal edge of the crystalline lens rests near the visual axis.

of glare and lenticular astigmatism. Considering the large zonular defect and concerns about scleral suture longevity, a pars plana lensectomy and vitrectomy followed by implantation of an anterior chamber (AC) intraocular lens (IOL) is a very acceptable option. Although a formidable challenge, phacoemulsification performed under regional block anesthesia has 1 potential advantage—avoiding a vitrectomy. To do this, I would first place iris retractors in 4 quadrants and then

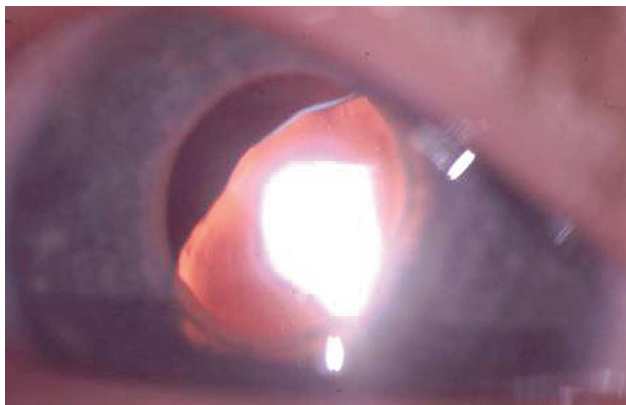


Figure 3. (Masket) Through the red reflex view, the edge of the crystalline lens is scalloped and in proximity to the visual axis.

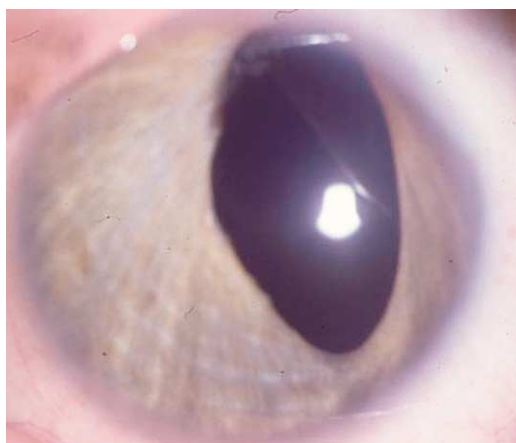

Figure 4. (Masket) The left eye has postsurgical pupil enlargement in the vertical meridian and is aphakic.

cover the zonular defect with a dispersive ophthalmic viscosurgical device (OVD) such as Viscoat[®] (sodium hyaluronate 3%–chondroitin sulfate 4%) or Vitrac[®] (hyaluronate 3%) before creating a capsulorhexis. A bent #30 needle may be necessary to initiate a capsule tear given the zonular laxity. I would then use 2 disposable Mackool capsule retractors (Impex) in the superior–temporal quadrant to hook the capsulorhexis edge to serve as artificial zonules for surgical support.

I have reported on the advantages of bimanual phacoemulsification for cataracts with large zonular defects (D.F. Chang, MD, “Bimanual Phaco for Cataracts with Zonular Dialysis,” video presented at the annual meeting of the American Academy of Ophthalmology, Anaheim, California, USA, October 2003). The reduced irrigation inflow of this system reduces posteriorly directed hydrostatic pressure against the lens and zonules and may reduce the risk for fluid misdirection

syndrome. The snug incisions should minimize incisional fluid leak, which would otherwise draw prolapsing vitreous to the wound. The ability to dissociate the irrigation and aspiration ports can also allow the surgeon to separate the irrigating port from the zonular defect as much as possible. Finally, the smaller instrument profiles may be more maneuverable in the setting of multiple iris and capsule retractors. Bimanual irrigation/aspiration (I/A) would provide these same advantages compared to a coaxial I/A setup.

If the capsular bag is successfully preserved without vitreous loss, there are several options for IOL placement. Although a Cianni modified capsular tension ring (CTR) (Morcher) or Ahmed capsular tension segment (CTS) (Morcher) would provide the most secure fixation to the capsular bag, neither device is approved by the U.S. Food and Drug Administration (FDA). One could subjectively assess the overall degree of bag support after placing a CTR in the bag. If the residual support was deemed too insecure for bag implantation (which is likely), one could consider placing an AC IOL or a foldable 3-piece IOL in the sulcus. For the latter, the haptics would be oriented along an axis perpendicular to the quadrant of missing zonules. If this were not a stable orientation, the IOL could be oriented with 1 haptic directed inferonasally. The unsupported superotemporal haptic would then be sutured to the iris using a modified McCannel suture.¹ This latter option, or an AC IOL, would be acceptable choices if the capsular bag tore and only portions of the inferotemporal capsule remained after phacoemulsification is completed.

Depending on the symptomatic improvement in the right eye, the reports of glare in the left eye should be carefully reevaluated. Because of the enlarged and eccentric pupil, placement of a Kelman-style, 4-point-fixated AC IOL may produce significant glare from the exposed haptic. Suturing the pupil may cause excessive decentration of the opening. Therefore, if the glare symptoms were tolerable, continued aphakic contact lens wear would afford the opportunity to wait for newer options in the future. One possibility would be a sulcus-sutured artificial iris implant (Ophtec), which is currently in a phase II trial in the U.S.

DAVID F. CHANG, MD
Los Altos, California, USA

Reference

1. Chang DF. Siepser sliplink for McCannel iris suture fixation of subluxated intraocular lenses. *J Cataract Refract Surg* 2004; 30:1170–1176

■ This interesting case presents several clinical challenges. Knowledge of the patient's level of contact lens tolerance and whether current correction is achieved with rigid or soft lenses are important factors. The 2-line difference between the potential acuity measurement in the left eye and the contact lens acuity might be due to undercorrected cylinder with a soft contact lens or a less-than-ideal current contact lens prescription. The patient's functional visual deficit is, for the most part, due to the position of the subluxated crystalline lens equator in the right eye and the vertical enlargement of the poorly functional pupil in the left eye.

Assuming the patient is contact lens tolerant, I would initially attempt to rehabilitate the left eye in the simplest way. With the exception of the superior zone, the left eye appears to have fairly generous residual iris. Pupilloplasty with transcorneal McCannel suturing inferiorly and superiorly will likely produce a much more functional pupil. The defect superiorly need not be closed completely by suturing that portion of the iris predominantly in the midperiphery to leave an "iridectomy" superiorly that would be well tolerated and of functional value. The final position of the new pupil is likely superotemporal, as in the right eye, based on the current configuration of the iris anatomy in the left eye. This procedure, combined with an optimal contact lens fitting, would likely provide the best potential visual function in the left eye.

I would assess the patient's response to the intervention in the left eye before considering surgical therapy in the right eye, which might be deferred if there is substantial improvement in the glare disability in the left eye. Indeed, if the subluxation in the right eye has been progressive, the crystalline lens may continue to spontaneously move out of the visual axis if simply left alone.

If invasive surgery in the right eye is initially deferred, a neodymium:YAG (Nd:YAG) laser iridotomy should be considered as a patient such as this is at risk for acute pupillary block glaucoma if there is increased forward mobility of the crystalline lens. While the scalloped appearance of the lens equator strongly suggests

complete absence of zonules in that area, Nd:YAG laser photodisruption of visible residual zonules can help move the lens equator farther out of the visual axis, improving aphakic contact lens acuity.

If contact lens intolerance is a central issue, IOL implantation must be considered. With progressive subluxation in the right eye, I would not rely on residual zonule for long-term support. Therefore, any scleral-supported posterior chamber (PC) IOL placement in the right eye would require 2-point scleral fixation, whether direct or obtained via a Cionni modified CTR or Ahmed CTSs (Morcher). Although scleral-fixated CTRs and CTSs are adjustable to a degree as far as centration is concerned, the ectopic pupil in the right eye (and the left eye even after repair) might make good optic-to-pupil alignment a challenge. In this patient, I would strongly consider peripheral iris fixation of a foldable acrylic IOL using transient pupillary capture of the optic while the haptics are fixated to peripheral iris with McCannel sutures.^{1,2} This approach (possibly combined with pars plana lensectomy) would likely provide better IOL-to-pupil alignment and greatly reduce the risk for the optic edge lying within the ectopic pupil.

GARRY P. CONDON, MD
Pittsburgh, Pennsylvania, USA

References

1. Condon GP. Simplified small-incision peripheral iris fixation of an AcrySof intraocular lens in the absence of capsule support. *J Cataract Refract Surg* 2003; 29:1663–1667
2. Stutzman RD, Stark WJ. Surgical technique for suture fixation of an acrylic intraocular lens in the absence of capsule support. *J Cataract Refract Surg* 2003; 29:1658–1662

■ We are told this patient with congenital ectopia lentis is otherwise healthy, which is significant because up to 69% of such cases may involve underlying systemic pathology such as Marfan's syndrome, homocystinuria, Weill-Marchesani syndrome, hyperlysenemia, and sulfite oxidase deficiency, to name a few.¹ Given this patient's strong desire for improved visual function and his surprisingly good PAM visual acuities (one might have anticipated significant refractive amblyopia in such a case), surgical intervention should be offered.